

Auscultation of the Heart

Bernard Karnath, MD

William Thornton, MD

Auscultation of the heart can provide clues to the diagnosis of many cardiac abnormalities, including valvular heart disease, congestive heart failure, and congenital heart lesions. Despite recent developments in noninvasive cardiac testing, the stethoscope used for auscultation remains the most valuable diagnostic tool for physicians conducting cardiac examinations of their patients. The diaphragm of the stethoscope can detect high-frequency sounds, such as systolic ejection murmurs, whereas the bell of the instrument can detect low-frequency sounds, such as S₃ and S₄ gallops or the diastolic rumble of mitral stenosis. These examinations should occur in a quiet environment, with ambient noise minimized. This article outlines a systematic approach to auscultation of the heart and discusses the significance of the heart sounds and murmurs heard during auscultation.

TECHNIQUE

A systematic approach should be followed when listening to the heart. According to one such method, the examiner should first auscultate at the right upper sternal border and next at the left upper sternal border; the examiner should then proceed down the left sternal border by a process called *inching*,¹ with the final point of auscultation being the apex. Proceeding in the reverse order is also appropriate (and more hemodynamically based), as long as a sequence is followed.

Each point of auscultation generally correlates with a cardiac valve (Figure 1) and thus enables detection of murmurs associated with valvular abnormalities. For example, the murmur of aortic stenosis is heard best at the right second interspace (parasternally), the murmur of pulmonic stenosis is heard best at the left second interspace (parasternally), the murmur of tricuspid stenosis is heard best along the lower left sternal border, and the murmur of mitral stenosis is heard best at the apex. In contrast, murmurs of regurgitation can radiate far from the point of origin; the murmur of aor-

AUSCULTATION OF THE HEART

Points of Auscultation

- Aortic area (right second intercostal space)
- Pulmonic area (left second intercostal space)
- Tricuspid area (midleft sternal border)
- Mitral area (fifth intercostal space, midclavicular line)

tic regurgitation originates over the aortic area but radiates to the apex, and the murmur of mitral regurgitation originates at the apex and radiates to the axilla.

HEART SOUNDS

Auscultation of the precordium with a stethoscope will reveal an audible S₁ and S₂. These normal heart sounds are generated by valve closures (Figure 2). Closure of the mitral and tricuspid valves produces S₁, which is heard best at the apex of the heart. A split S₁ may be heard along the left lower sternal border, where the tricuspid component might also be audible. Abnormal S₁ sounds occur when there is disease of the mitral valve. For example, the S₁ may be loud and have a “snapping” quality in patients with mitral stenosis as a result of rapid closure of the mitral valve²; conversely, S₁ may be diminished in the presence of mitral regurgitation.

S₂ correlates with closure of the aortic and pulmonic valves and is heard best at the base of the heart. Physiologic splitting of S₂ occurs as a result of aortic valve closure preceding pulmonic closure. The splitting of S₂ is maximal at the end of inspiration and heard best at the second left interspace (parasternally). Increased splitting at the end of inspiration results from delayed

Dr. Karnath is an Assistant Professor of Internal Medicine and Dr. Thornton is a Professor of Medicine, Division of Cardiology, University of Texas Medical Branch, Galveston, TX.

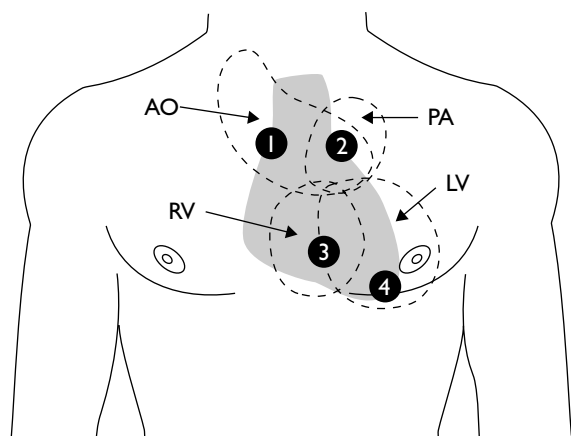


Figure 1. Points of auscultation. AO = aortic area; LV = left ventricle; PA = pulmonic area; RV = right ventricle; 1 = right second intercostal space; 2 = left second intercostal space; 3 = midleft sternal border (tricuspid area); 4 = fifth intercostal space, midclavicular line (mitral [apical] area).

pulmonic closure caused by right ventricular filling during inspiration. Fixed splitting of S_2 can occur in patients with atrial septal defect, pulmonic stenosis, and right bundle branch block. True fixed splitting occurs only with atrial septal defect (ie, it does not vary with respirations); in pulmonic stenosis and right bundle branch block, there is a widened split S_2 that does vary with inspiration. Paradoxical splitting of S_2 occurs when S_2 splits on expiration and closes on inspiration; it is most commonly encountered in patients with aortic stenosis and left bundle branch block.

S_3 is low pitched, is heard best at the apex with the bell of the stethoscope, and is usually not present in healthy adults. An S_3 can be a normal variant in children and may persist into young adulthood.³ An S_3 gallop (also called a *ventricular gallop*) is frequently a sign of left ventricular failure. The S_3 gallop can be heard in patients with any condition resulting in rapid ventricular filling and volume overloading (eg, mitral/aortic insufficiency).

S_4 is a presystolic low-pitched sound occurring just before S_1 that is heard best at the apex with the bell of the stethoscope; it is normally not present in healthy persons. An S_4 (aortic) gallop is encountered in patients with any condition causing decreased ventricular compliance, such as hypertension, aortic stenosis, coronary artery disease, and hypertrophic cardiomyopathy. These conditions cause increased resistance to ventricular filling following atrial contraction. An S_4 gallop is never heard in the presence of atrial fibrillation because of absent atrial contraction.

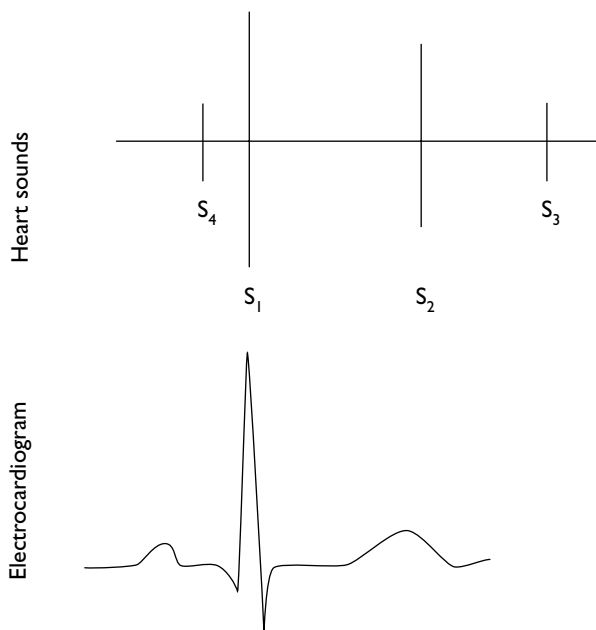


Figure 2. Schematic representation of normal and abnormal heart sounds. A normal electrocardiogram is provided for correlation to the cardiac cycle.

HEART MURMURS

A heart murmur is defined according to its intensity, frequency, quality, configuration, timing, duration, and radiation. Murmurs can be either systolic or diastolic (**Figure 3**). The intensity or loudness is graded on a 6-point scale.³ Grade 1 murmurs are very faint and generally heard only after focusing on the sound. Grade 2 murmurs are faint but heard immediately on placing the stethoscope on the precordium. Grade 3 murmurs are moderately loud, whereas grade 4 murmurs are loud. Grade 5 murmurs are very loud and can be heard when the stethoscope is partly off the precordium. Grade 6 murmurs are also very loud and can be heard with the stethoscope completely off the precordium. Grade 4 and higher murmurs also are associated with a thrill.

Systolic Murmurs

Systolic murmurs are classified according to their timing and duration into either the midsystolic ejection or pansystolic (holosystolic) category (**Figure 4**). Systolic ejection murmurs are caused by outflow obstruction. Their intensity peaks in midsystole and is described as a crescendo-decrescendo or “diamond-shaped” murmur (**Figure 4A**). Systolic ejection murmurs can be heard in patients with aortic stenosis, pulmonic stenosis, and hypertrophic cardiomyopathy as obstruction to outflow

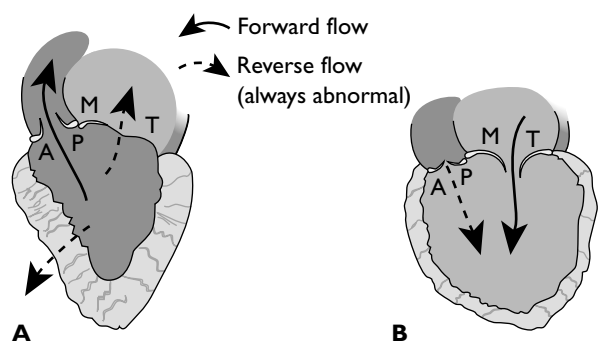


Figure 3. Pathophysiology of systolic (A) and diastolic (B) murmurs. A = aortic valve; M = mitral valve; P = pulmonic valve; T = tricuspid valve.

occurs. Systolic ejection murmurs can also be heard in conditions of high cardiac output, such as anemia and thyrotoxicosis. Finally, aortic regurgitation—besides causing a diastolic regurgitant murmur—can also cause a systolic ejection murmur as the volume of ejected blood from the left ventricle is increased.

Pansystolic murmurs result from retrograde flow from a high-pressure chamber to a low-pressure chamber. Common conditions associated with pansystolic murmurs include ventricular septal defect, mitral insufficiency, and tricuspid insufficiency (Figure 4B).

Innocent murmurs. The innocent systolic ejection murmur is the most common murmur heard in school-aged children.³ The innocent murmur is a midsystolic murmur heard best at the left lower sternal border; it has a diamond-shaped intensity. The murmur does not radiate and usually is grade 1 to 2. Innocent murmurs result from turbulent blood flow generated by left ventricular ejection of blood.

Aortic stenosis. The murmur of aortic stenosis is a systolic ejection murmur that peaks early in systole. The murmur is harsh in quality and medium pitched. It is heard best at the second right interspace (parasternally) and often radiates to the carotid arteries. As the severity of the stenosis worsens, the murmur peaks later in systole, and the closure of the aortic valve component of S_2 decreases in intensity and is delayed. This delay results in a paradoxical splitting of S_2 , with the closure of the aortic valve and the closure of the pulmonic valve merging on inspiration (Figure 5B). Conditions associated with aortic stenosis include the presence of a congenital bicuspid aortic valve, rheumatic fever, and aortic sclerosis.

Hypertrophic cardiomyopathy. Hypertrophic cardiomyopathy leads to outflow obstruction resulting in turbulent ejection of blood from the left ventricle dur-

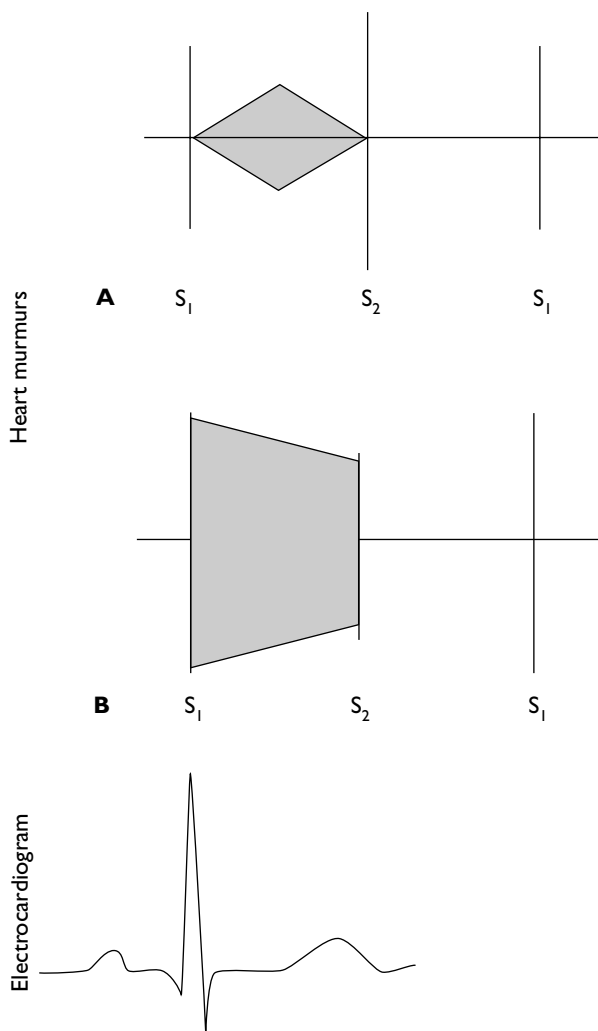


Figure 4. Schematic representation of (A) a systolic ejection (crescendo-decrescendo) murmur and (B) a pansystolic (holosystolic) murmur. A normal electrocardiogram is provided for correlation to the cardiac cycle.

ing systole. The resulting systolic ejection murmur is a harsh, medium-pitched murmur heard best at the left lower sternal border. The murmur can be manipulated with the Valsalva maneuver, which results in increased loudness.^{4,5}

Mitral regurgitation. The murmur of mitral regurgitation is a pansystolic murmur generated as blood regurgitates from the left ventricle to the left atrium (Figure 4B). The murmur is a blowing, medium-pitched sound heard best at the apex that radiates to the axilla. S_1 is very soft. This murmur is heard in patients with infective endocarditis, degenerative valvular diseases (eg, mitral valve prolapse), and rheumatic heart disease. If

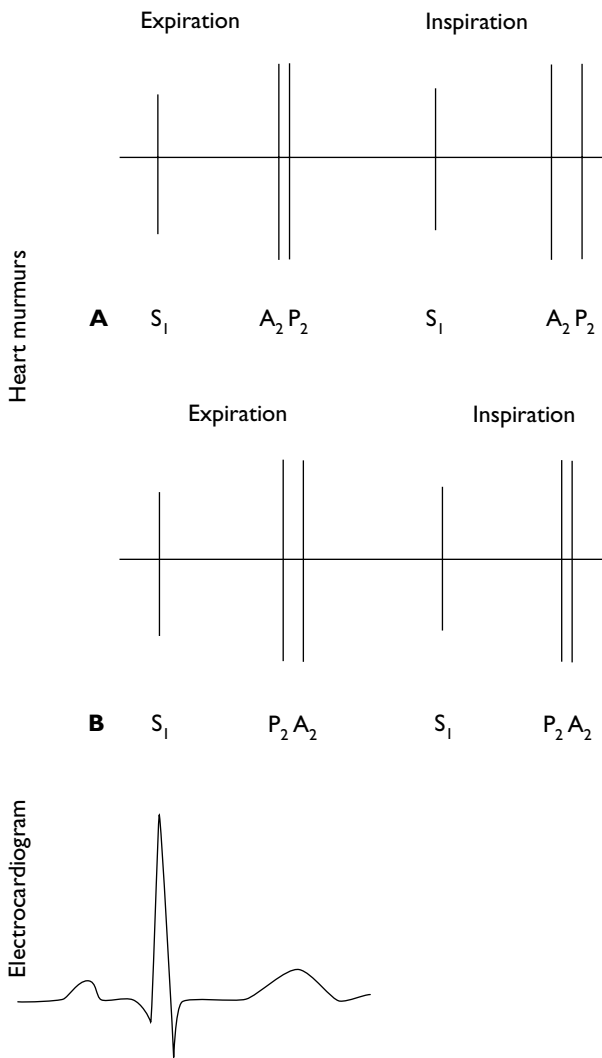


Figure 5. Schematic representation of (A) normal physiological splitting of S₂ during inspiration and (B) paradoxical splitting of S₂ during expiration. A normal electrocardiogram is provided for correlation to the cardiac cycle. A₂ = closure of the aortic valve; P₂ = closure of the pulmonic valve.

mitral valve prolapse is present, then a midsystolic click may be heard, followed by a late systolic murmur.

Tricuspid regurgitation. The murmur of tricuspid regurgitation is a blowing, pansystolic murmur of medium pitch heard best at the left lower sternal border that increases on inspiration and radiates to the right of the sternum. The most common disorder in which a murmur of tricuspid regurgitation is heard is right ventricular failure, which causes chamber dilation and resultant enlargement of the tricuspid orifice.

Ventricular septal defect. A ventricular septal defect is a congenital lesion that results in a persistent open-

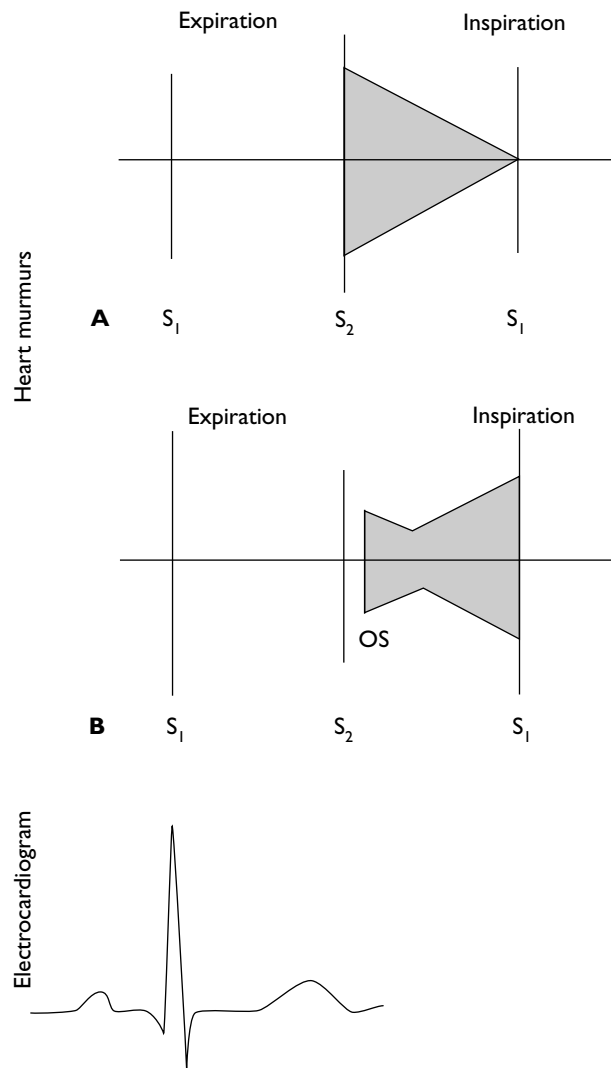


Figure 6. Schematic representation of (A) a diastolic murmur in aortic insufficiency and (B) a presystolic rumble in mitral stenosis. A normal electrocardiogram is provided for correlation to the cardiac cycle. OS = opening snap.

ing of the interventricular septum, allowing blood to pass from the high-pressure left ventricle into the low-pressure right ventricle.⁶ The resultant murmur is a high-pitched pansystolic murmur heard best along the left lower sternal border.

Atrial septal defect. The murmur usually associated with an atrial septal defect is a systolic ejection murmur heard best at the left lower sternal border across the pulmonic valve area. This murmur results from increased flow across the pulmonic valve caused by the increased filling of the right ventricle resulting from left-to-right shunting in the atria. With large atrial septal defects,

there is excess blood flow across the tricuspid valve, which causes a middiastolic murmur at the left lower sternal border.³ S₂ is widely split and fixed as a result of delayed closure of the pulmonic valve.

Diastolic Murmurs

Diastolic murmurs can be classified according to their etiology (Figure 5). Diastolic regurgitant murmurs result from retrograde flow across an incompetent aortic or pulmonic valve, whereas diastolic filling murmurs result from turbulent flow across the mitral or tricuspid valve. The diastolic murmur of aortic insufficiency is a decrescendo murmur (Figure 6A), whereas the murmur of mitral stenosis produces a rumble and can be preceded by an opening snap (Figure 6B).

Aortic regurgitation. The murmur of aortic regurgitation occurs during diastole as the aortic valve fails to close completely and blood regurgitates from the aorta back into the left ventricle. The murmur is a high-pitched decrescendo murmur heard best along the left lower sternal border. Of note, aortic regurgitation is sometimes associated with 2 other murmurs as well; a systolic ejection murmur can result from the volume overload of the left ventricle resulting in increased flow across the aortic valve, and an Austin Flint murmur (a middiastolic murmur heard at the apex) can be generated by impingement of the regurgitant flow on the anterior leaflet of the mitral valve.

Mitral stenosis. The murmur of mitral stenosis is a low-pitched presystolic rumbling sound associated with a loud S₁ and preceded by an opening snap just after S₂ is heard. The murmur is located at the apex and heard best with the bell of the stethoscope. Rheumatic heart

disease is the most common underlying condition in patients with this murmur.

Other Murmurs

The murmur associated with patent ductus arteriosus is a continuous murmur heard over the pulmonic area. The murmur is caused by a high-pressure continuous shunt as blood flows continuously during both systole and diastole from the aorta, through the patent ductus arteriosus, into the pulmonic artery. The murmur is described as a continuous, rough, “machinery-type” murmur.³

CONCLUSION

The stethoscope remains the centerpiece of diagnostic tools for clinicians performing cardiac examinations of their patients. Many cardiac abnormalities can be diagnosed at the bedside with the use of a stethoscope. Auscultation is the most cost-effective diagnostic test for patients with cardiac abnormalities. **HP**

REFERENCES

1. Harvey WP. Cardiac pearls. *Dis Mon* 1994;40:41–113.
2. Shipton B, Wahba H. Valvular heart disease: review and update. *Am Fam Phys* 2001;63:2201–8.
3. Engle MA. Heart sounds and murmurs in diagnosis of heart disease. *Pediatr Ann* 1981;10:84–93.
4. Stapleton J. Manipulating cardiac murmurs. *Chest* 1982; 81:135–6.
5. Constant J. *Bedside cardiology*. 5th ed. Philadelphia: Lippincott Williams and Wilkins; 1999.
6. Moodie DS. Diagnosis and management of congenital heart disease in the adult. *Cardiol Rev* 2001;9:276–81.

Copyright 2002 by Turner White Communications Inc., Wayne, PA. All rights reserved.